

DATE **PRESENTING CLINICAL SIGNS**
History of persistent cough

8-18-21

INTERPRETED BY **CYTOLOGY SUBMISSION**
FNA of thoracic mass

L.D. McGill, DVM,
Ph.D, DACVP

PATIENT **OBSERVATIONS**

Lung mass: Submitted are 3 excellent videos of moderate to excellent collections of cells from the lung mass in Sadie. Two of the videos include large numbers of inflammatory cells that are neutrophils, macrophages and necrotic debris. One of the videos has collections of cells that are packeted. These cells have characteristics of epithelial cells from the lung tissue. These epithelial cells are likely derived from pulmonary tissue. They demonstrate slight anisokaryosis.

Daisy Miles

SPECIES **INTERPRETATION OF THE FINDINGS & FURTHER RECOMMENDATIONS**

Canine
Lung mass - Suggestive of pulmonary carcinoma with secondary pyogranulomatous inflammation and necrosis

BREED **COMMENTS**

Golden mix
There are packets of cells in one of the videos that suggest the likelihood of a pulmonary carcinoma. There is extensive inflammation in and around the proliferative tissue. This inflammation is pyogranulomatous. It's very prominent in most of the videos. Due to the apparent carcinoma cells, an unfavorable prognosis is expected. A follow-up biopsy either by exploratory or punch biopsy will be required to confirm the diagnosis.

SEX

FS

AGE **The information and recommendations provided are based on the images presented by the referring veterinarian. No evaluation can be communicated regarding pathology that was not visible in the image/video clips provided.**

14 years

WEIGHT Thank you for this referral. If the clinical or image interpretation does not parallel your findings or if I can be of any further assistance please contact me.

49.8#

HOSPITAL NAME **L.D. McGill, DVM, Ph.D., DACVP**
8288 Top of the World Drive
Cottonwood Heights, UT 84121
ldmcgill.vetpath@gmail.com
cell: 801-865-1220

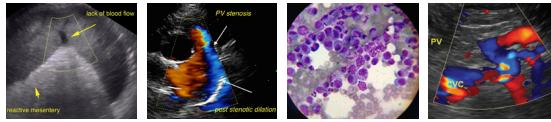
Santa Clara Animal
Hospital

REFERRING VET

Dr. Zulaf

INVOICE NUMBER

80287



DATE

8-18-21

INTERPRETED BY

L.D. McGill, DVM,
Ph.D, DACVP

PATIENT

Daisy Miles

SPECIES

Canine

BREED

Golden mix

SEX

FS

AGE

14 years

WEIGHT

49.8#

HOSPITAL NAME

Santa Clara Animal
Hospital

REFERRING VET

Dr. Zulaf

INVOICE NUMBER

80287

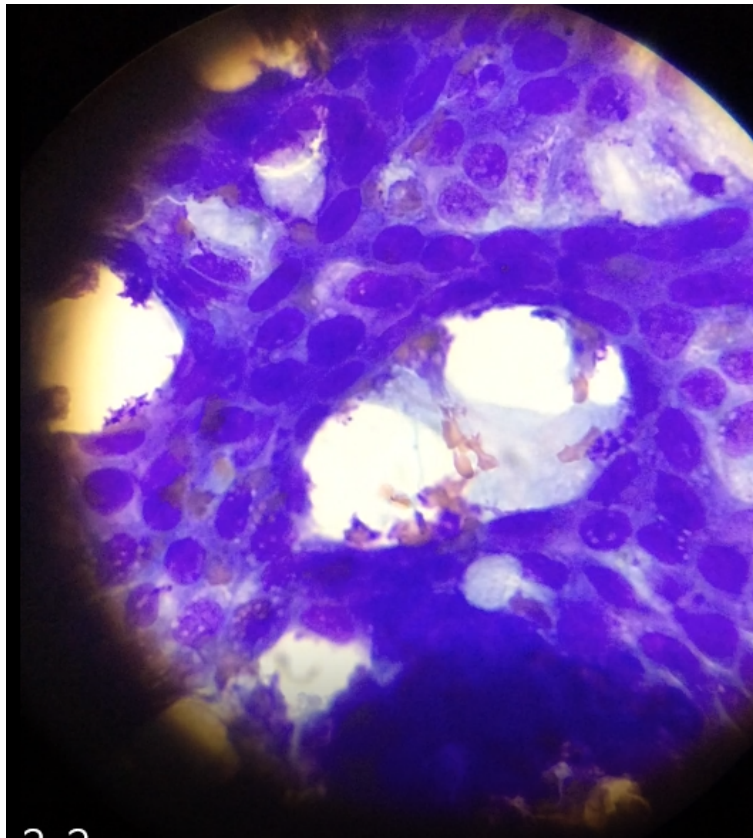


Image shows cells that appear to be carcinoma cells collected from the lung in Sadie. Maybe a collection of mucus in the center.